Glomerulonephritis

Presented by:
RoaaAmer
KSAU-HS

Outline

- Mechanisms of Glomerular Injury
- Clinical manifestation schema
- Common causes of GN
- Cases

Mechanisms of Glomerular Injury

- Circulating immune complex
- In situ immune complex
- Cell-mediated
- Activation of the alternative complement pathway
- Cytotoxic antibodies

Clinical manifesttattions & presenttattion of Glomerular Disease

- Asymptomatic hematuria & Asymptomatic proteinuria (Isolated urinary abnormalities)
- Nephrotic Syndrome
- Acute Nephritic Syndrome
- Rappidly progressive glomerular disease
- CKD

Let's talk Medicine

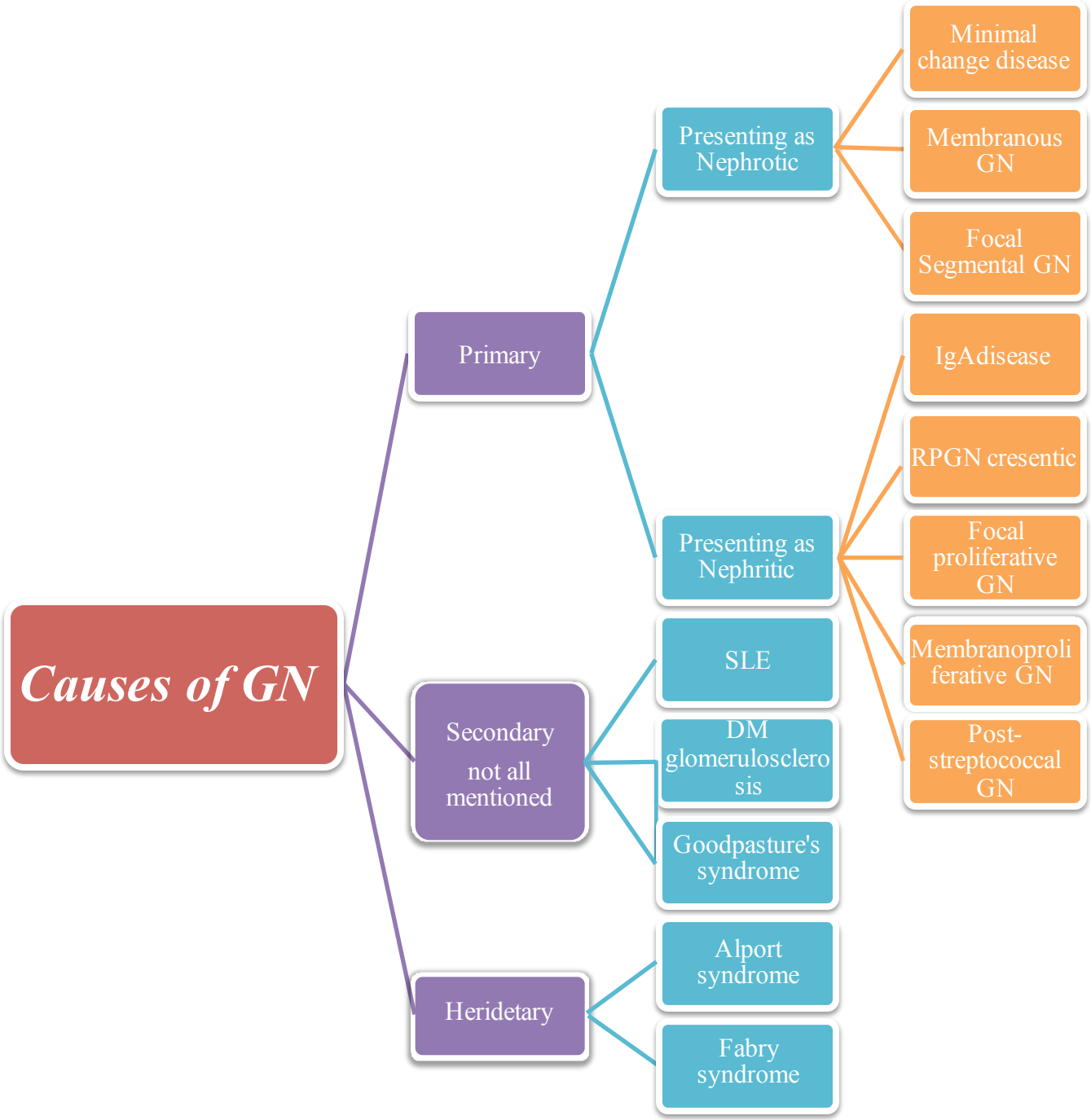
Causes of GN
Primary
Secondary not all mentioned
Heridetary
Presenting as Nephrotic
Presenting as Nephritic
Minimal change disease
Membranous GN
Focal Segmental GN
IgAdisease
RPGN cresentic
Focal proliferative GN
Membranoproliferative GN
Post-streptococcal GN
SLE
DM glomerulosclerosis
Goodpasture's syndrome
Alport syndrome
Fabry syndrome

Primary Causes of Nephrotic Syndrome

1.Minimal Change Disease:

- ✓✓ Most common cause of nephrotic syndrome in children under the age of 7 Y\O
- ✓✓ No evidence on light microscopy
- ✓✓ Electron microscopy: PODOCYTE FUSION (EFFACEMENT)
- ✓✓ Selective proteinuria
- ✓✓ Very responsive to steroids

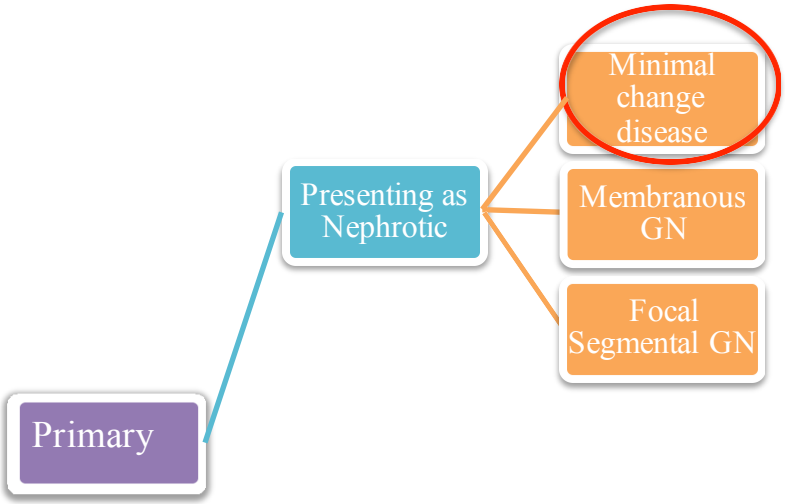

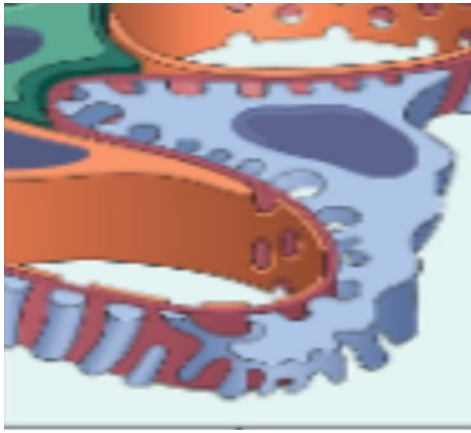

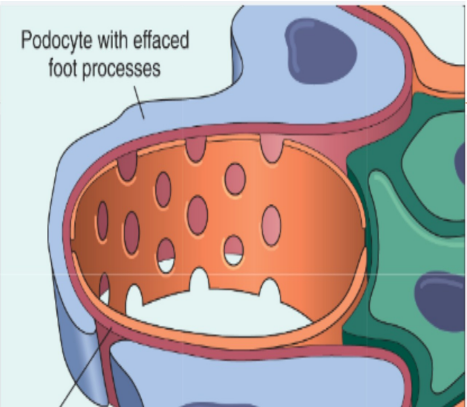

Primary Causes of Nephrotic Syndrome

2. Membranous GN:

- ✓✓ Subepithelial deposition of immune complexes
- ✓✓ BM thickening
- ✓✓ Can lead to CKD 30%
- ✓✓ Non-selective proteinuria

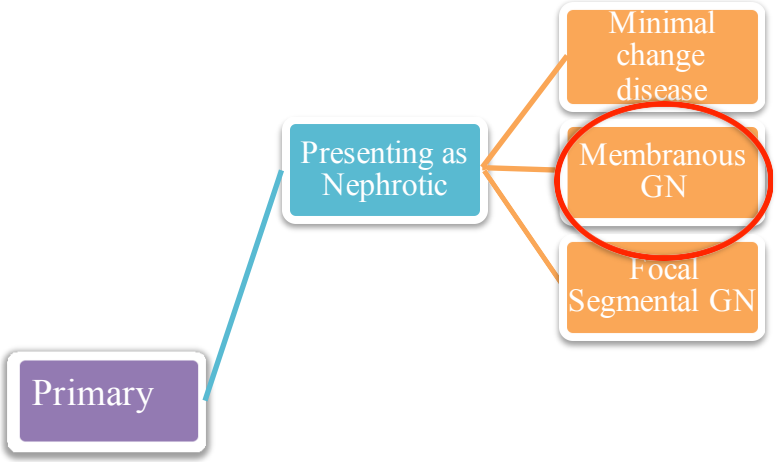

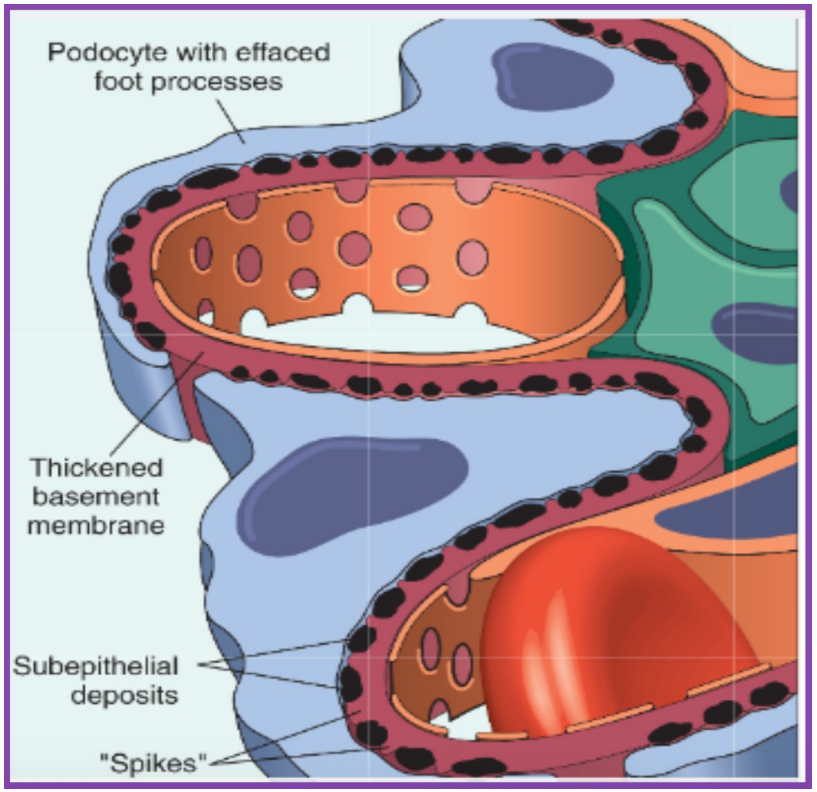

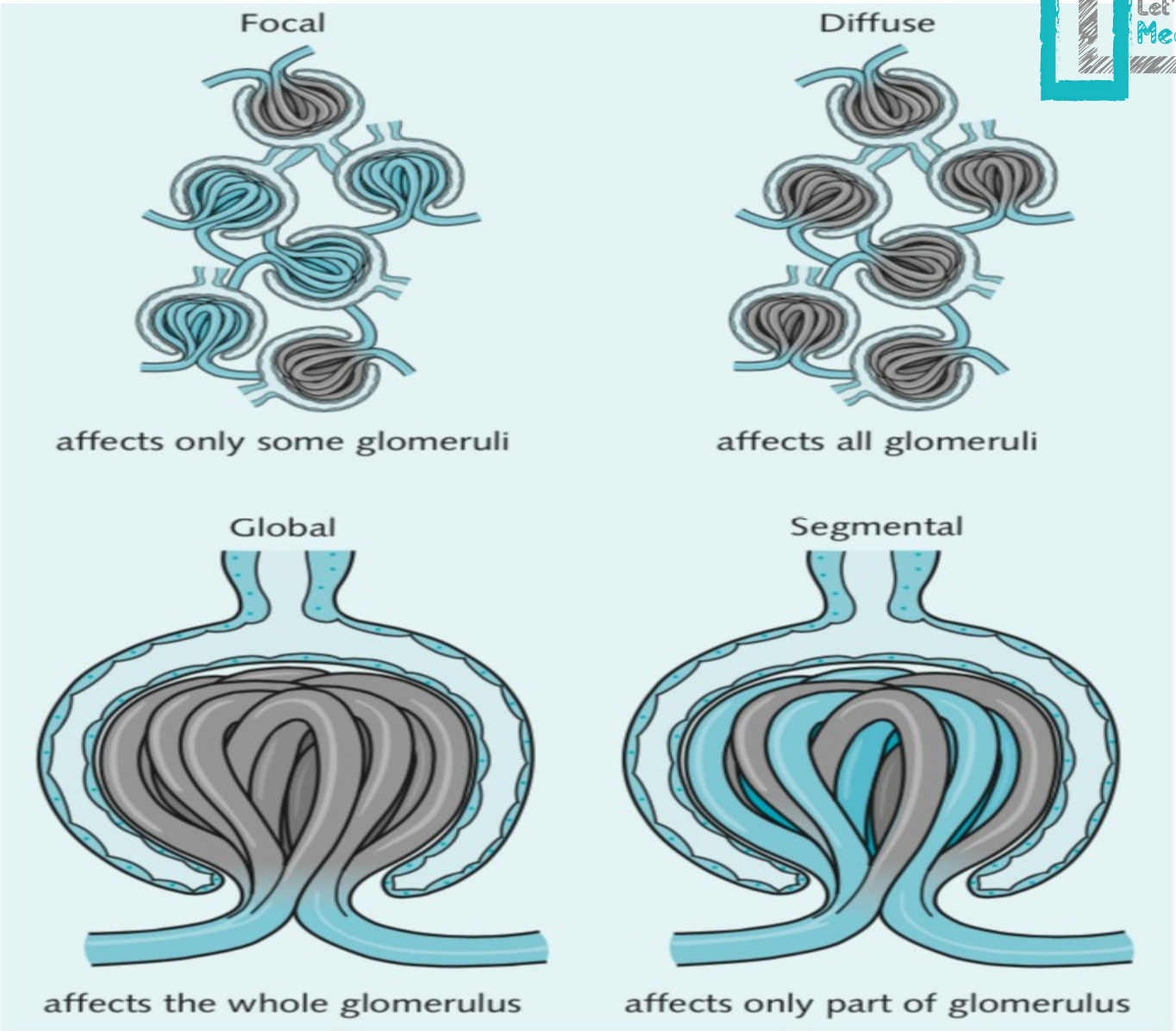
Focal
affects only some glomeruli
Diffuse
affects all glomeruli
Global
affects the whole glomerulus
Segmental
affects only part of glomerulus

Primary Causes of Nephrotic Syndrome

3. Focal Segmental GN:

- ✓✓ Most common cause of nephrotic syndrome in adults (in the clinical setting)
- ✓✓ Focal podocyte collapse (effacement) and sclerosis (hyalinosis)
- ✓✓ Most develop CKD eventually
- ✓✓ Non-selective proteinuria
- ✓✓ Hematuria

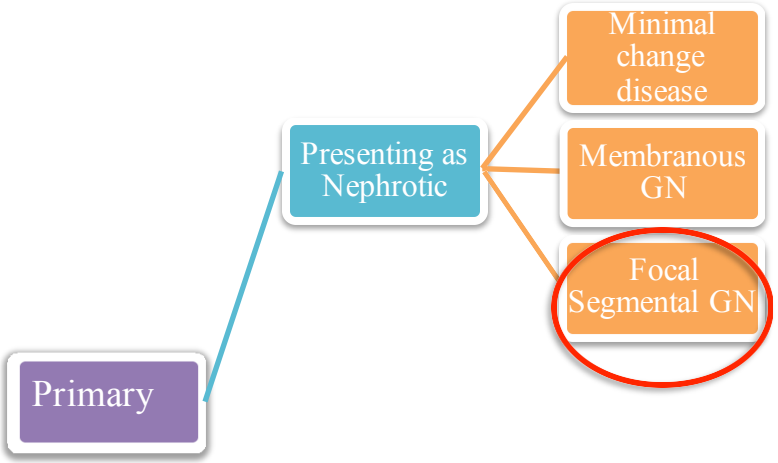

Primary Causes of Nephritic Syndrome

1. IgA GN (Berger's Disease):

- ✓✓Most common primary GN WORLDWIDE
- ✓✓HSP (pupuric rash, joint pain, GI symptoms, and GN)
- ✓✓Most common cause of recurrent microscopic or gross hematuria
- ✓✓Usually after URTI
- ✓✓Mesangial proliferation and deposition of IgA and C3 (high).

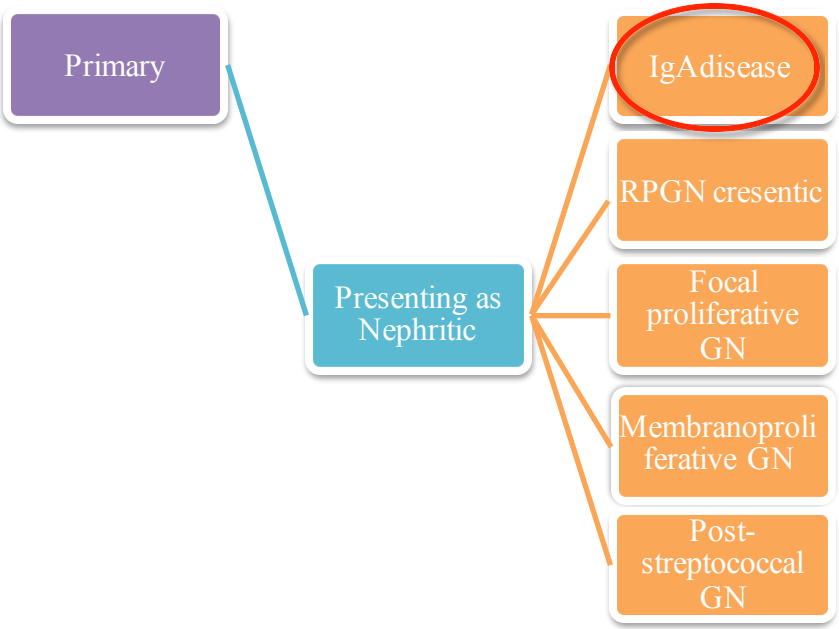

Primary Causes of Nephritic Syndrome

2. Rapidly Progressive (cresentic) GN:

- ✓✓Severe glomerular injury
- ✓✓Will lead to fibrin leakage that stimulate proliferation of epithelial cells and macrophages
- ✓✓Reducing the blood supply
- ✓✓Rapid deterioration and loss of the renal function in = < 2 weeks
- ✓✓NOTE: any GD can develop

into RPGN if they have rapid deterioration

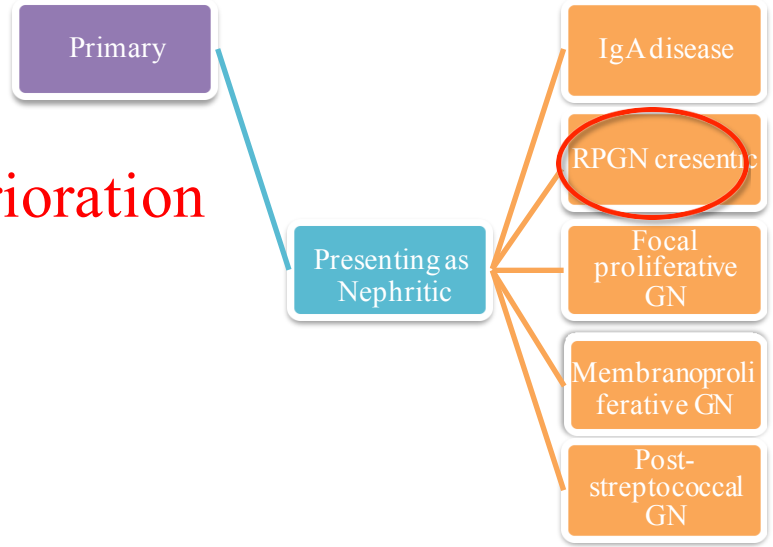

Primary Causes of Nephritic Syndrome

4. Membranoproliferative GN:

- ✓✓Diffuse global BM thickening
- ✓✓Rare
- ✓✓Nephrotic\nephritic syndrome

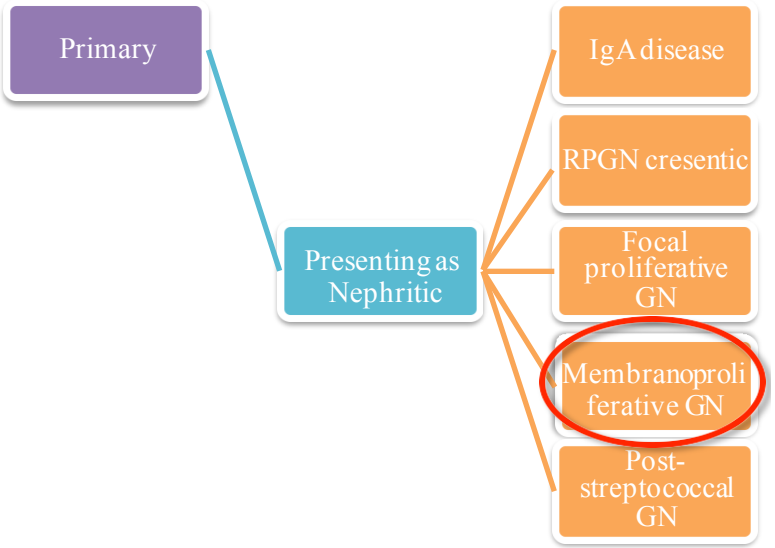

Primary Causes of Nephritic Syndrome

5. Post-streptococcal GN:

- ✓✓1-3weeks after strep. Infection of the tonsils, pharynx, and skin
- ✓✓Gross hematuria
- ✓✓Self-limited
- ✓✓ASO titers and low C3

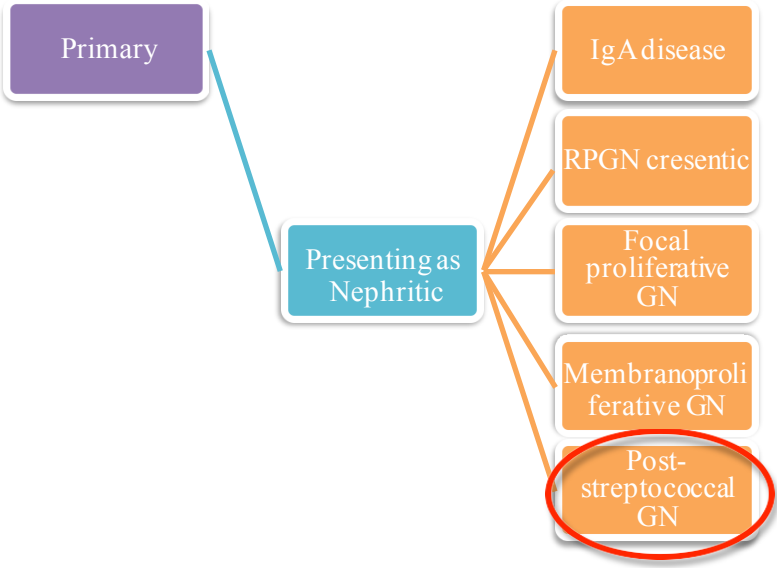

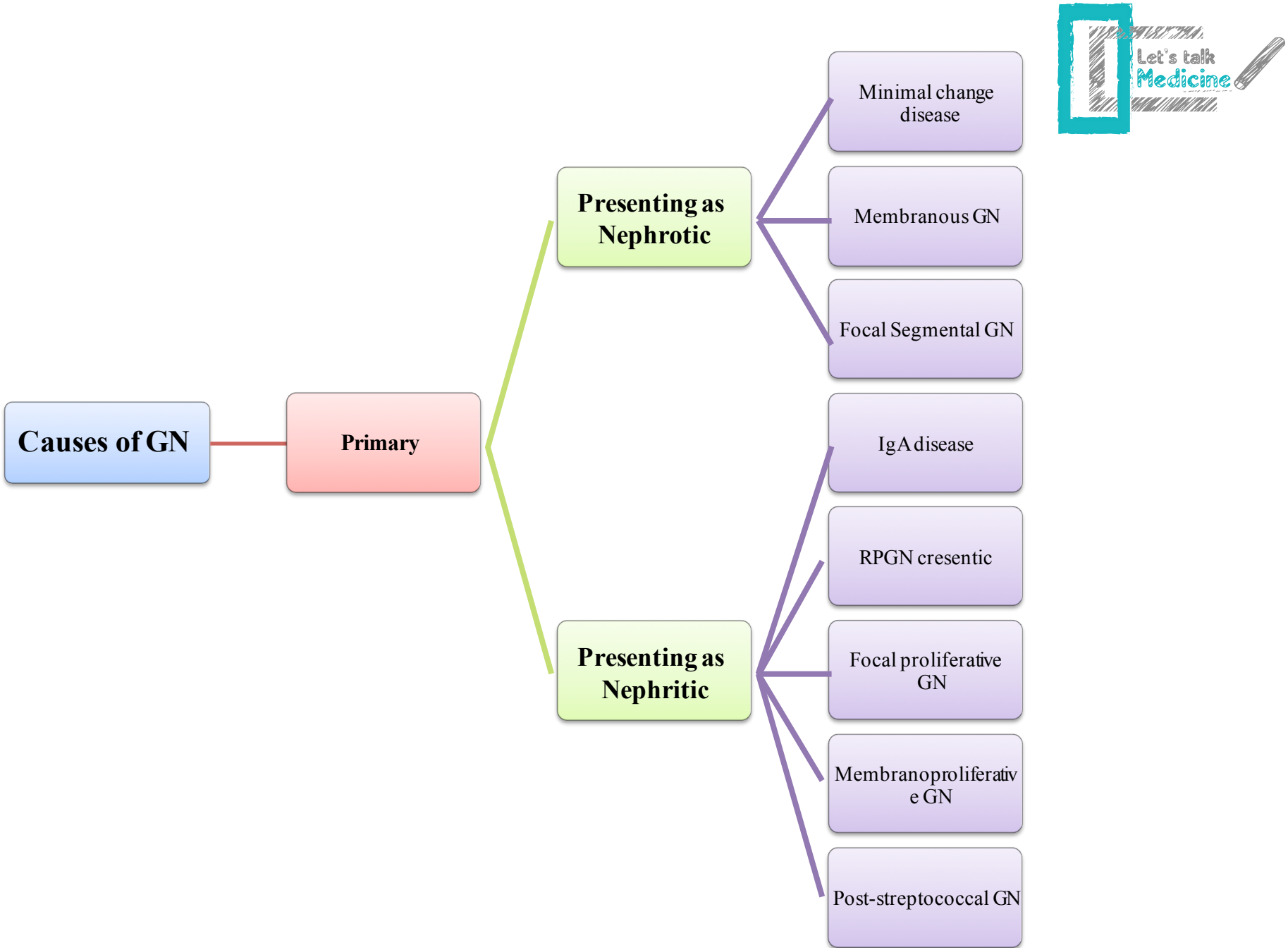
Let's talk Medicine
Causes of GN
Primary
Presenting as Nephrotic
Minimal change disease
Membranous GN
Focal Segmental GN
Presenting as Nephritic
IgA disease
RPGN cresentic
Focal proliferative GN
Membranoproliferative GN
Post-streptococcal GN

Case 1

- John is a 6 years old male child presented to you with puffiness of the eyes, lower limb edema, and some ascites.

1. What do you suspect?
2. What investigations you should order?
3. What is the most probable underlying pathology in this case?
4. What is your management?

A: Case 1

A1: Nephrotic syndrome

A2: 24 hr urine collection, urinalysis, serum albumin, lipid profile.

A3: Minimal change disease

A4: Steroids responsive and the general measurements for GN (ACE, diuretics, statins, treat the complications)

Case 2

- Mike is a 29 year old male presented to you with headache, decrease urine output, and change in the color of the urine (the ptx mentions a recent sore throat and tonsillitis 3weeks ago).

1. What is the most probable Dx after R\O other causes?
2. What investigations you would order?
3. What is the management in this case?

A: Case 2

A1: post-strep. GN

A2: urinalysis, ASO titer, C3 (specific)

A3: supportive and treat if there is complications

Case 3

- Sara is a 45 year old female presented to the ER with edema, malar rash, and joint pain, urinalysis showed RBC casts, and serum showed hypoalbuminuria and creatinine levels was extremely high.

1. What is the most probable diagnosis?
2. What is the proper management of this patient?
3. What investigation will you order?

A: Case 3

A1: RPGN

A2: immediate steroids and immunosuppressant

A3: check for SLE (ANA), ANCA, anti-GBM, ASO titers

Clinical presentation	Primary glomerular cause	Secondary cause
Asymptomatic haematuria	Mesangial IgA glomerulonephritis (GN) other GN Exercise-induced haemoglobinuria	Henoch-Schönlein purpura (HSP) systemic lupus erythematosus (SLE) bacterial endocarditis
Asymptomatic proteinuria	Mesangial capillary GN any other GN focal segmental glomerulosclerosis shunt nephritis any cause of renal scarring	HSP SLE SLE Bacterial endocarditis Polyarteritis nodosa severe long-standing hypertension pregnancy
Acute nephritic syndrome	Post-streptococcal GN non-streptococcal GN rapidly progressive GN focal proliferative GN mesangial IgA GN	SLE Microscopic polyangiitis Wegener's granulomatosis
Nephrotic syndrome	Minimal change disease Membranous glomerulonephropathy membranoproliferative GN focal segmental glomerulosclerosis	HSP SLE Tumour amyloid Diabetes mellitus drugs (e.g. penicillamine, gold) Bacterial endocarditis congenital nephrotic syndrome
Chronic kidney disease glomerulosclerosis	This develops as a long-term consequence of any of above diseases	

Let's talk Medicine

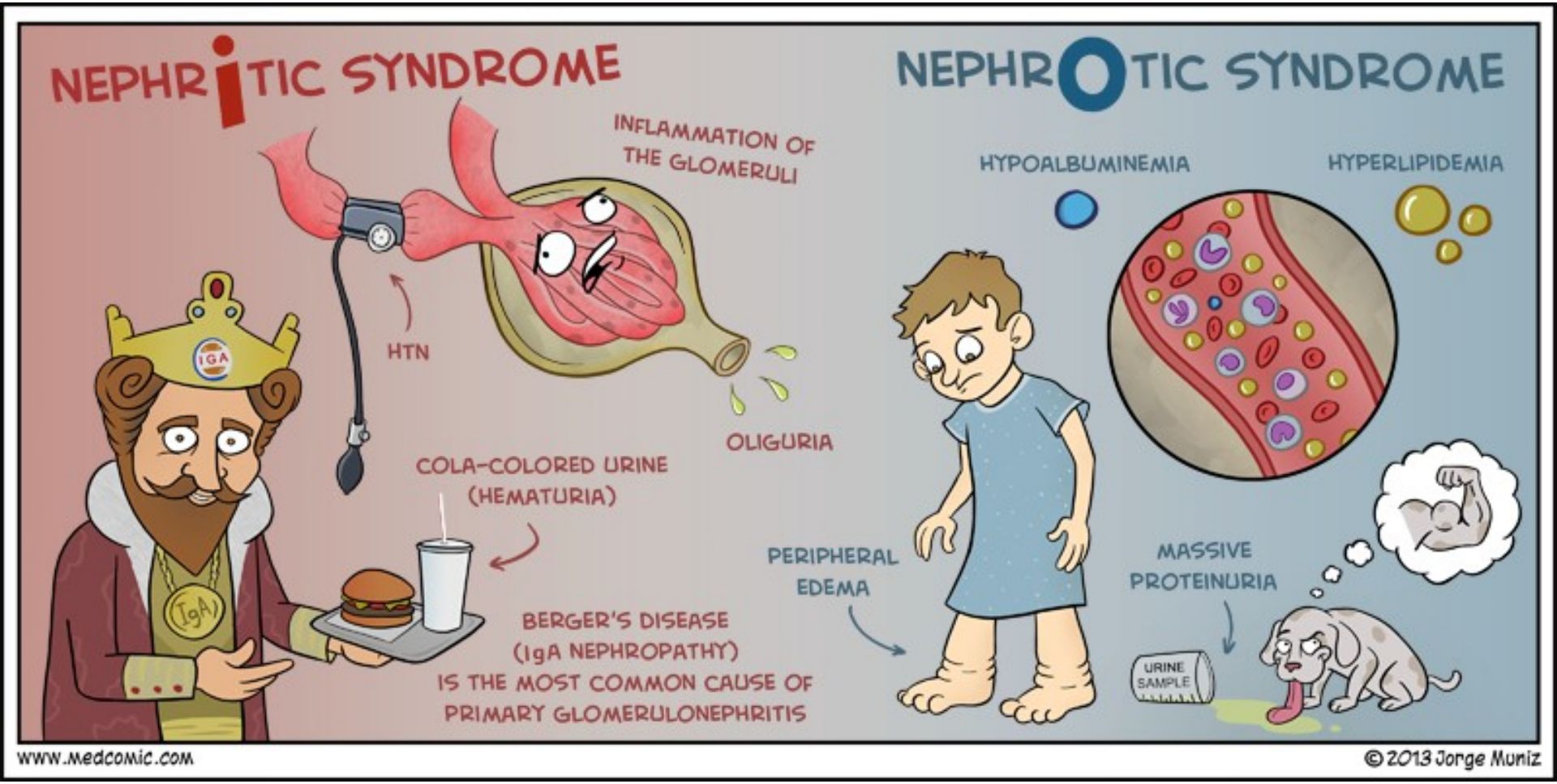

References

- Crash course
- Kumar and Clark's
- Organ system first aid
- Personal notes
- Batch 9's files, COMF, KSAU-HS

For any questions or comments please contact us at:

info@letstalkmed.com